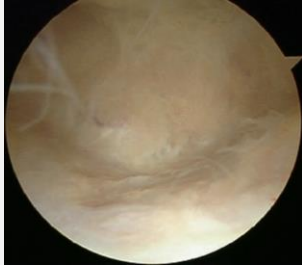


Ellbogenarthroskopie - standardisierter Rundgang und Bildgebung

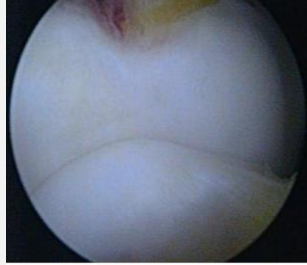
Standard Zugänge:

antero-lateral, dorso-zentral, hoch dorso-radial und Soft-Sport Portal und antero-mediales Portal

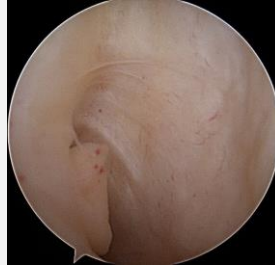
Diagnostischer Rundgang dorsales Kompartiment



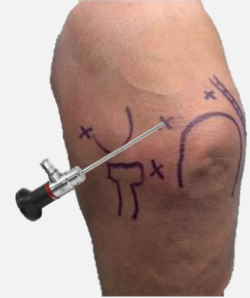Fossa olecrani



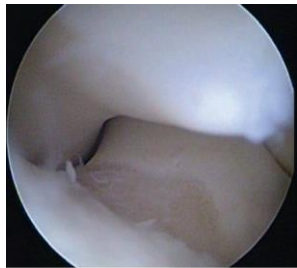
Olecranonspitze



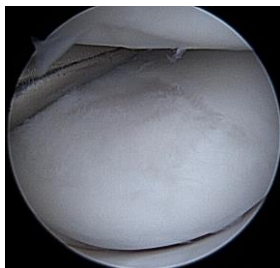
ulnarer Recessus



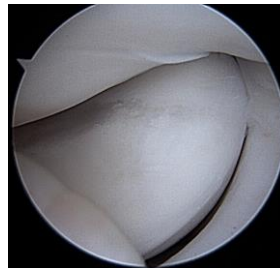
Diagnostischer Rundgang dorso-laterales Kompartiment



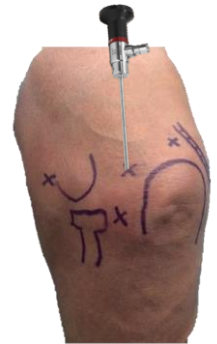
Incisura trochleae



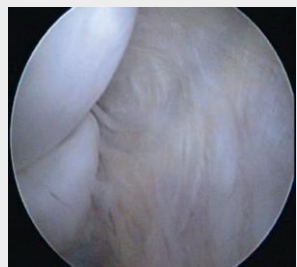
Radiuskopf
+ Capitellum



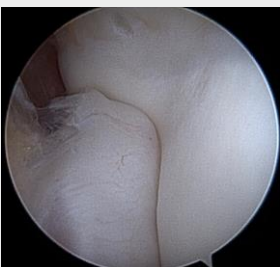Plica
humeroradialis



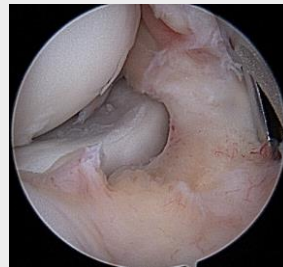Diagnostischer Rundgang ventrales Kompartiment



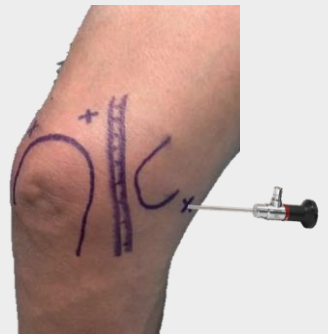medialer Gelenkspalt
Trochlea humeri und Ulna



Proc. Coronoideus
+ Trochlea

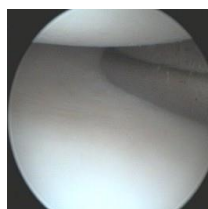


Radiuskopf
+ Capitellum

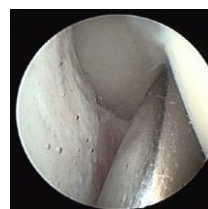

Instabilitätsbeurteilung

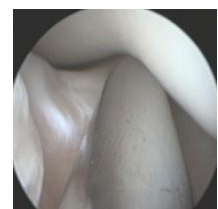PLRI



Humero-radial



PLRI 2



PLRI 3
Subluxierbares Coronoid