

Handgelenksarthroskopie – standardisierter Rundgang und Bildgebung



AGA KOMITEE

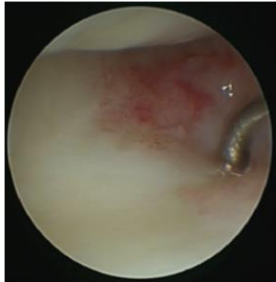Ellenbogen – Hand

Standard Zugänge:

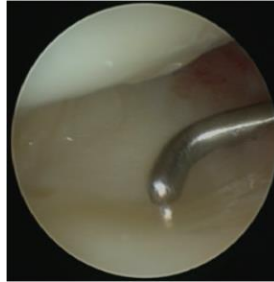
radio- und ulnokarpal: 3/4, 4/5, 6R; evtl. 1/2, 6U (Cave: Sensible Nerven)

mediokarpal: MCR und MCU

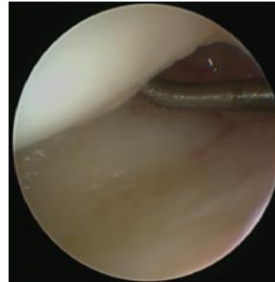
Diagnostischer Rundgang ulnokarpal



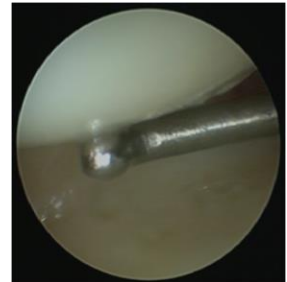
Rezessus
ulnocarpalis



TFCC/ Diskus
ulnocarpalis

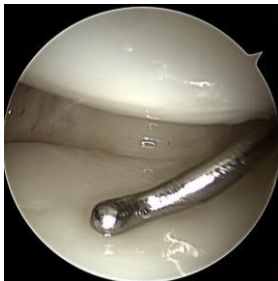

Lunotriquetrales
(LT) Band

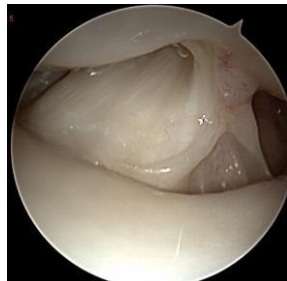


Knorpel ulnoproximale
Lunatumzirkumferenz

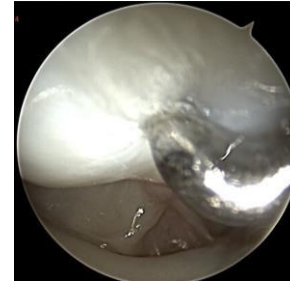
Diagnostischer Rundgang radiokarpal



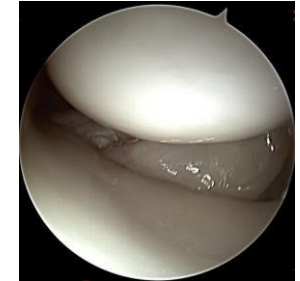
Radiolunäre
Gelenkfläche,
palmare Bänder



Testut-Band,
skapholunäres (SL)
Band zentraler Anteil

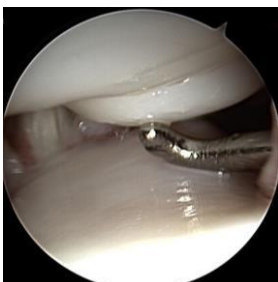

skapholunäres (SL)
Band zentraler +
dorsaler Anteil

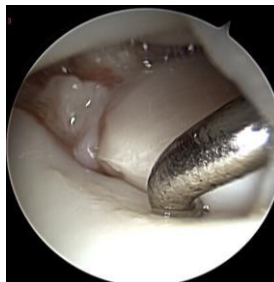

Radioskaphoidale
Gelenkfläche,
palmare Bänder

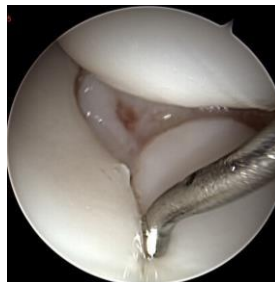Diagnostischer Rundgang mediokarpal



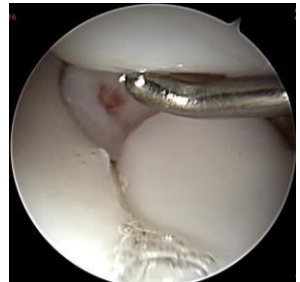Hamatumspitze



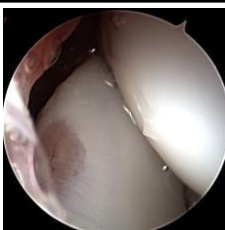
Lunotriquetraler
(LT) Gelenkspalt



skapholunärer (SL)
Gelenkspalt



Kapitatumkopf



Optional:
Skapho-trapezoidales (ST) Gelenk