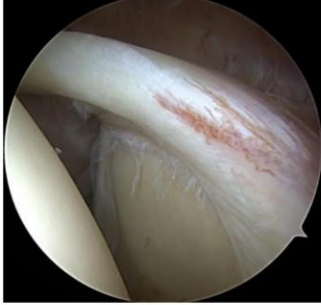


Schulterarthroskopie standardisierter Rundgang und Diagnostik

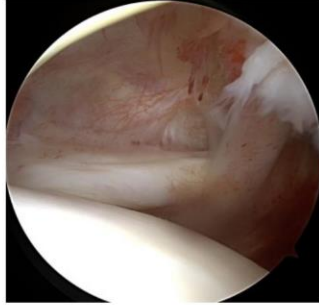
Standard Zugänge:

Dorsal, anterior (Rotatorenintervall), lateral (subacromial)

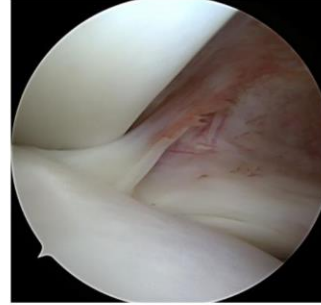
Standardperspektiven glenohumeral



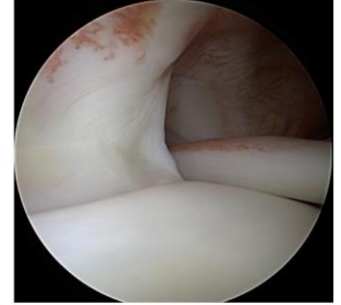
Bicepssehnenanker



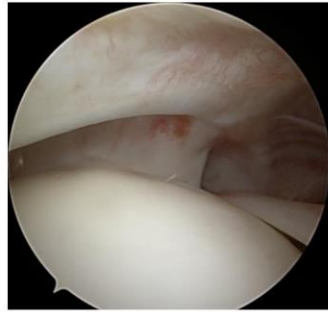
Rotatorenintervall



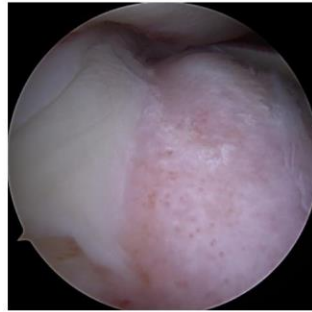SGHL/med. Pulley



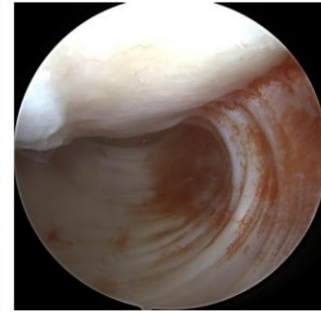
SSP/lat. Pulley



Rotator cable und crescent ISP-Insertion(bare area)

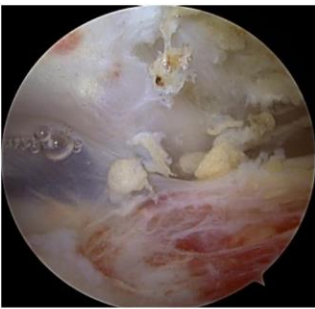


axillärer Rezessus

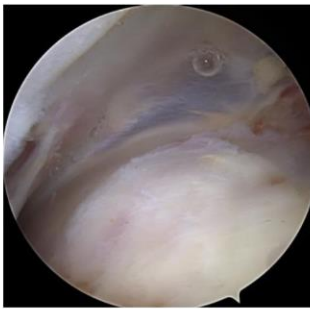

post. Labrum/Knorpel

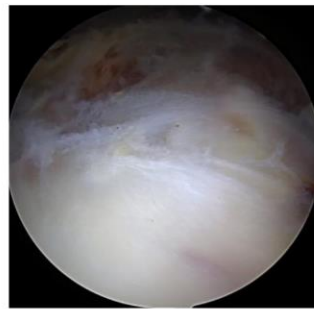
Standardperspektiven Subacromialraum



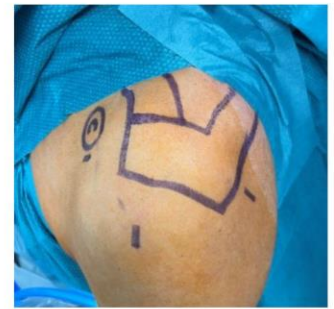SSP/CAL



SSP von dorsal

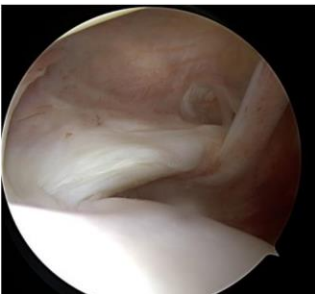

posterosuperiore RM
von lateral

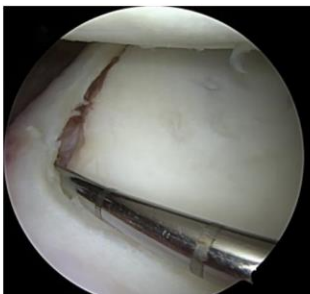


Standardportale

Zusatzeinstellungen/Tasthakenuntersuchungen



SSC-Insertion
(posterior lever push)



Tasthakenuntersuchung Labrum
und Bicepssehnenanker

